



Thomas J. Balshi,
DDS, FACP



Glenn J. Wolfinger,
DMD, FACP

Ultimate Smile Makeover



TEETH IN AN HOUR™

Radical makeovers of our bodies or our environments have become a fixture of the new century. But many factors can influence any individual's decision to seek out and embrace this dramatic form of self-improvement. In the following case study, the patient had reached mid-life before a dental crisis started him down the path to a profound physical transformation.

For most of his life, Bill had avoided any significant dental problems. He'd never endured chronic tooth pain or the embarrassment of discolored or unsightly teeth; he'd never undergone lengthy treatment.

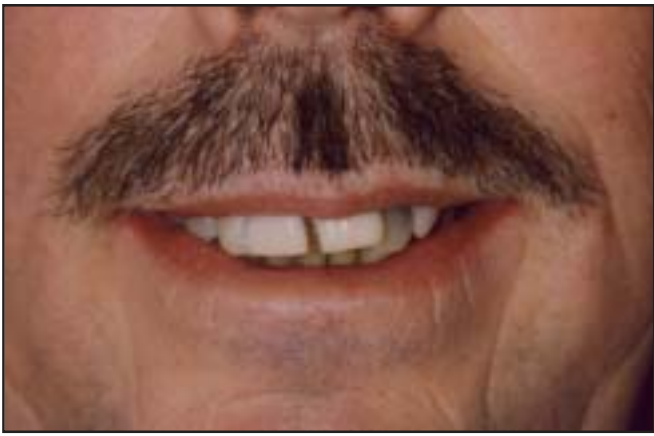

Pre-treatment Smile

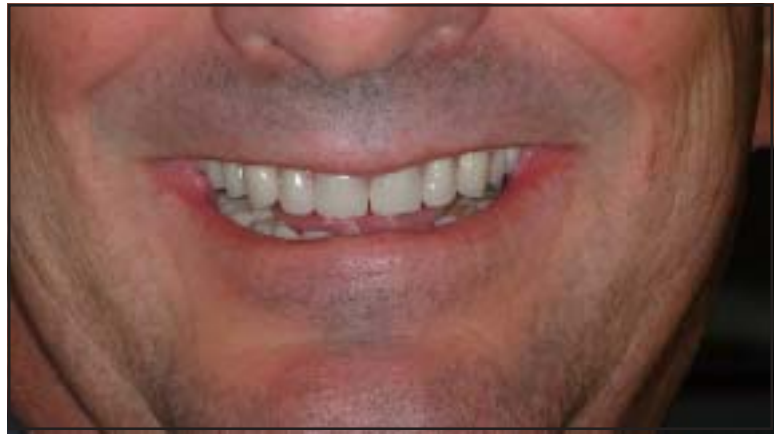

Post Teeth In An Hour™ Smile

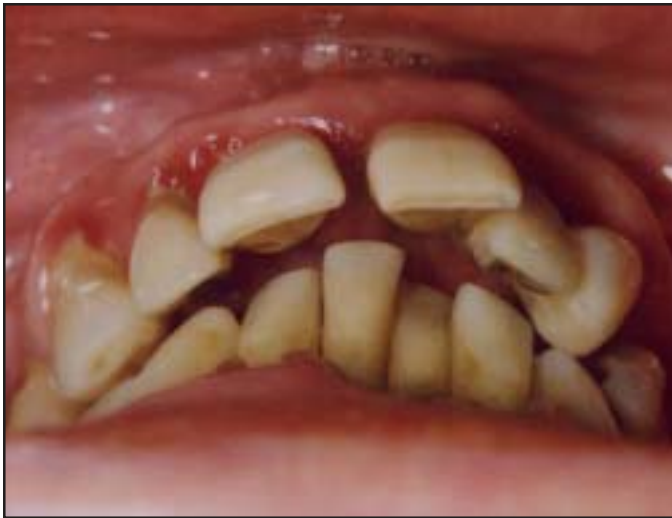He did have physical problems, however, including a heart murmur and high blood pressure. Thirty years of smoking more than a pack of cigarettes each day had also compromised his cardiovascular system. At 53, Bill finally underwent a triple-bypass surgery, after which his doctor had prescribed a blood thinner. According to Bill, "the prescribed medications caused a loosening of his teeth," with ensuing bone loss and dental abscesses. As Bill's ability to



Pre-treatment smile



Post Teeth In An Hour™ smile



Pre-treatment Angle's Class II Malocclusion

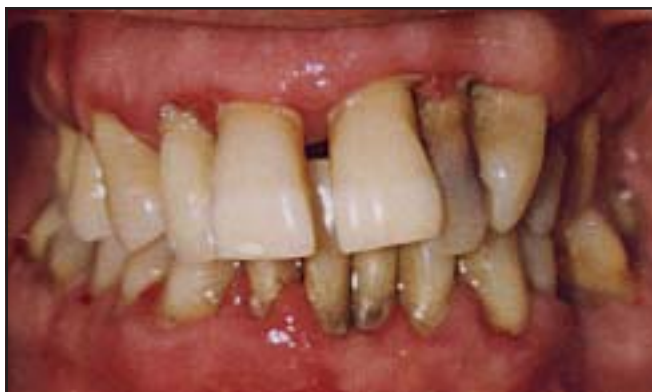Bill returned to Prosthodontics Intermedica for another comprehensive prosthodontic evaluation. His prosthodontist recommended extraction of all of his teeth, while his periodontist suggested that a few teeth might be saved and used to fabricate a tooth-supported restoration.

Due to the advanced bone loss and tooth mobility, Bill was told that conventional treatment would be too unpredictable. He opted to have all his teeth removed. Since he felt that financial restraints wouldn't permit him to replace all his teeth with implants immediately, Bill chose, instead to receive Teeth in a Day™ in his lower jaw, while having a denture created for the upper jaw.

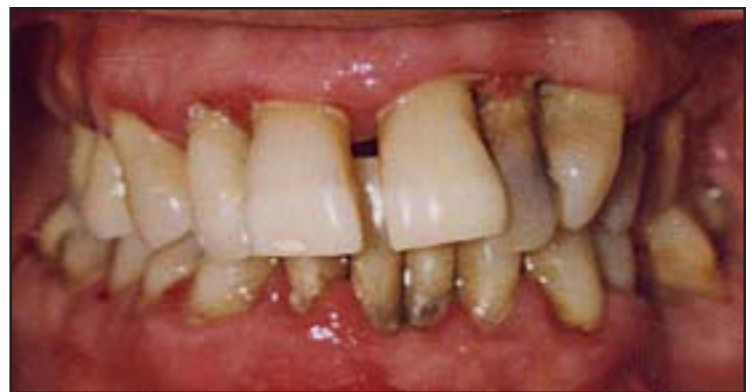chew foods deteriorated, he sought advice.

Faced with a diagnosis of periodontally hopeless teeth with advanced mobility, significant bone loss, and poor esthetics, Bill felt torn about what to do. He sought other opinions. Three years after his heart surgery,

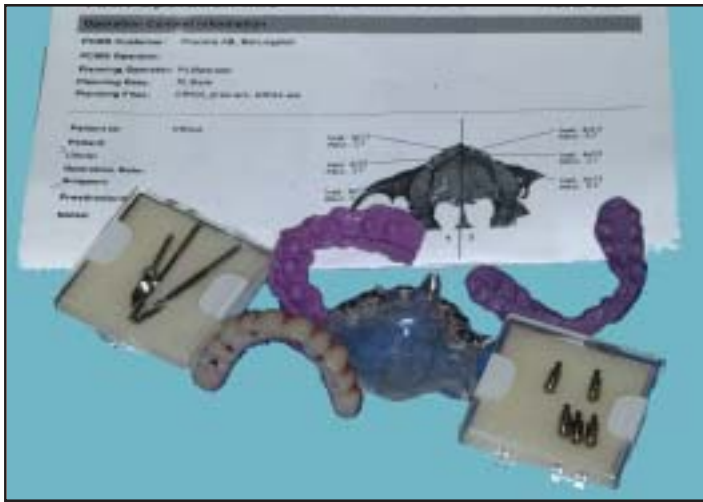
At the time of extraction, all the soft tissue and abscesses were removed from the tooth sockets. Seven Brånemark implants (Nobel Biocare, Yorba Linda, California) were then immediately placed in the lower jaw, and a Teeth in a Day™ prosthesis was



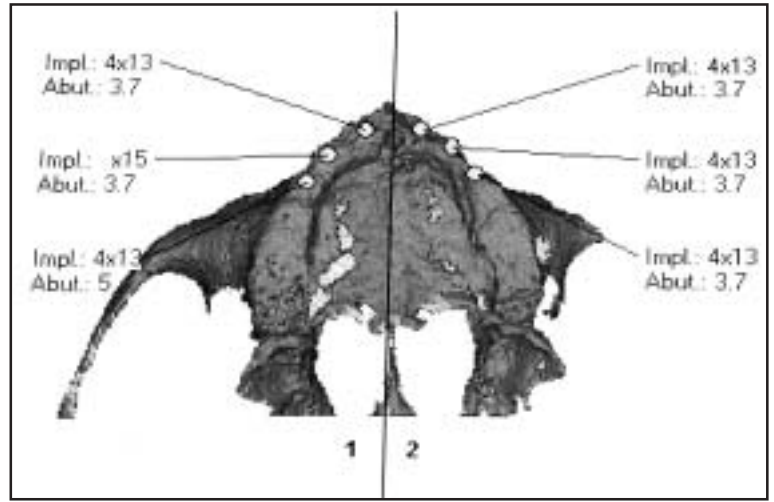
Pre-treatment collapsed bite relationship



Post-treatment Class I Occlusal Relationship



Nobel Biocare ARK Materials and Components



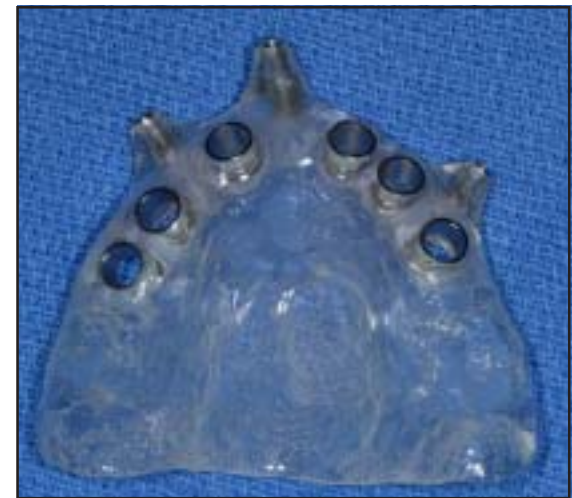ARK Map with Implant and Abutment Size Outlined

Teeth In An Hour™ uses pre-surgical three-dimensional computer planning allowing fabrication in advance of a highly precise final restoration.



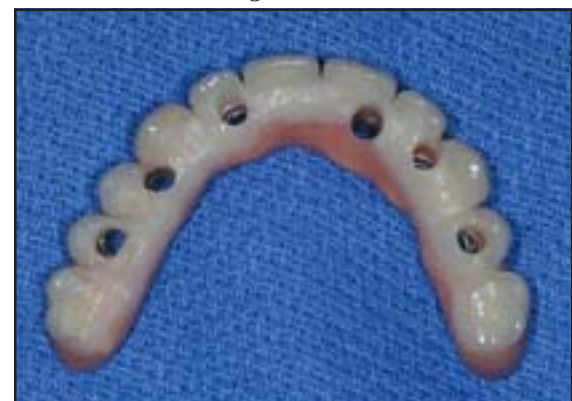Scanning Denture with Radiopaque Markers

created to fit on top of them. Bill went home that day wearing an immediate complete upper denture. In the days that followed, he reported very little pain or discomfort and only minimal swelling. Three months later, he received permanent versions of both the denture and the implant-supported prosthesis.



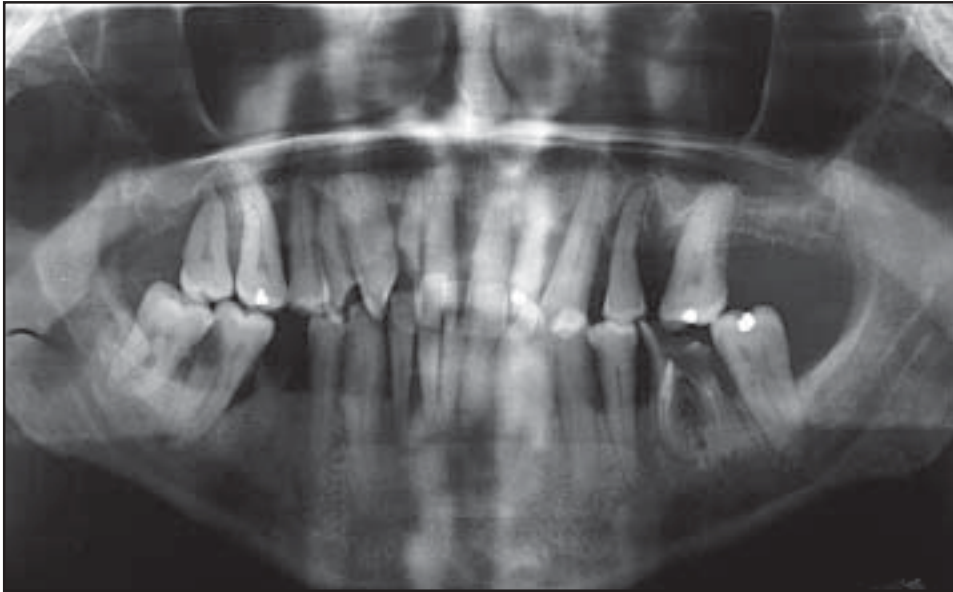
Surgical Guide

“The lower jaw restoration felt just like my own teeth,” Bill recounts. “I was thrilled.” In fact, he felt so enthusiastic about the initial change in his appearance that he consulted a plastic surgeon. He had become dissatisfied with excess facial tissue that he felt made him look tired and older than his years. He subsequently had a face lift, brow lift and eye lid lift, along with placement of a chin implant to enhance his jaw line.

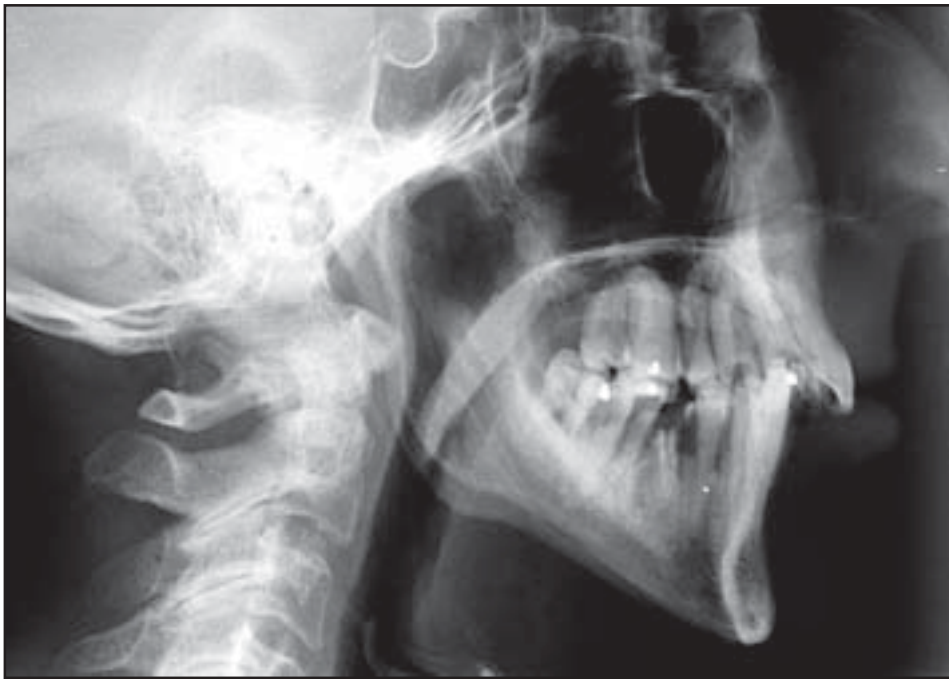


Maxillary Teeth In An Hour™ Prosthesis

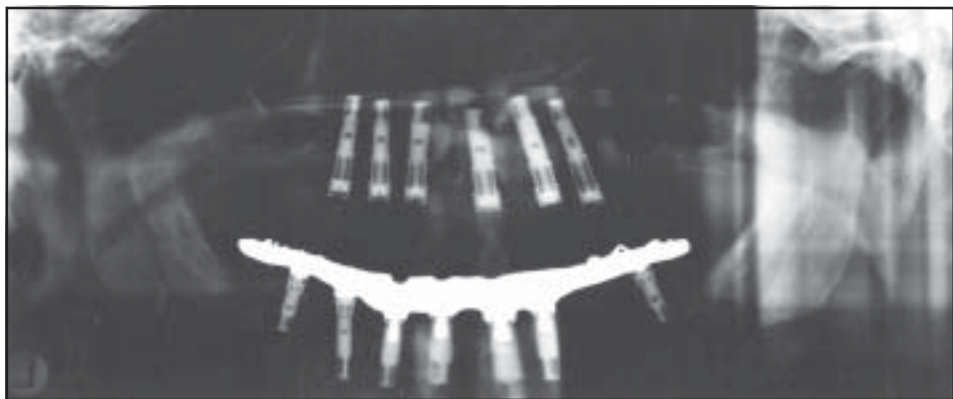
Although delighted with his new appearance and implant-supported teeth, Bill found the upper denture to be uncomfortable despite numerous adjustments and efforts to reline it. He finally concluded that replacing the upper denture with implant-supported teeth was no longer something he could regard as a luxury; it had become a necessity. A new Nobel Biocare surgical protocol – Teeth in an Hour™ – had just become available. This type of treatment allows patients to receive their implants and new teeth in about 35 minutes, versus the two to three hours required by the Teeth in a Day™



Pre-treatment Panoramic radiograph



Pre-treatment Lateral Cephalometric Xray



Post-Treatment Teeth In An Hour™ Panoramic Radiograph

procedure. Moreover, the patient leaves the prosthodontic office with a reinforced definitive prosthesis. This is all made possible due to the use of pre-surgical three-dimensional computer planning that allows for the fabrication of a highly precise definitive restoration in advance of the surgery.

Informed about this opportunity, Bill was eager to proceed. Since his upper denture looked good, an impression of it was made, and a clear copy of it was fabricated. Numerous radio-opaque markers were then placed within the clear denture. With that denture in the mouth, a CT scan was taken. Another scan was taken of the clear denture itself.

Working on a computer, these scans were aligned using the radio-opaque markers, and the surgeon determined exactly how the implants needed to be placed in order to achieve the best possible esthetic result. This information was then sent by modem to Nobel Biocare in Sweden where a computer guided the machining of a surgical guide that would help guarantee proper implant placement.

On the day of surgery, 20cc of blood were drawn and platelet-rich plasma (PRP, Harvest Technology) was harvested from the blood. Applying the platelet-rich plasma to the surgical area has been shown to expedite



Patient has a very active lifestyle. He is pictured here prior to Teeth In An Hour™ surgery with his “Catch of the Day.”

healing. Six small receptor sites were then precisely created in the upper jaw, exactly where the surgical guide dictated that they be positioned. Five 13mm-long Brånemark implants and one 15mm-long Brånemark implant were coated with the platelet-rich plasma and placed into the surgical site. Abutments were connected to the implants, and the carbon fiber-reinforced acrylic prosthesis that was created in advance was screwed into place on the abutments.

The post-operative instructions given were the same as those that Bill had received after his Teeth in a Day™ procedure. These included using ice for the first 40 hours and sticking to a moderately soft diet for a 12-week period. In addition, Bill was provided with antibiotics, pain medications, and steroids. The following day, he reported only the mildest discomfort and no

The Institute For Facial Esthetics

Continuing Education

Traditional 2-Stage Implant Protocol and

1-Stage TEETH IN A DAY™

Featuring the Brånemark System®

*Co-sponsored by Nobel Biocare USA, Inc.**

Course Dates:

September 20, 21, 22, 2004

January 17, 18, 19, 2005

April 11, 12, 13, 2005

September 12, 13, 14, 2005

Faculty:

Thomas J. Balshi, DDS, FACP

Glenn J. Wolfinger, DMD, FACP

Robert Winkelman, CDT, MDT

Time:

8:00 AM - 6:00 PM

Lunch 12:00 - 1:00 PM

Tuition:

\$ 1800

Location:

Institute for Facial Esthetics

467 Pennsylvania Avenue #201

Fort Washington, PA 19034

Credits:

Eligible for 24 hours of
continuing education credit

Educational Objectives: To teach and demonstrate the effect of osseointegrated dental implants on facial esthetics and general patient well-being; To provide clinical instruction and hands-on implant training; To provide clinical patient management before, during, and after dental implant rehabilitation; To provide post-prosthesis maintenance via home and professional oral hygiene.

Course Content: Includes the fundamentals of implant surgery and prosthetics, patient selection, treatment planning, drape and anesthesia, evaluation of implant sites, bone preservation, site preparation, implant placement, surgical closure, abutment connection, loading of implants, post-op instructions. Special considerations include graft areas, anatomic defects, immediate extractions sites, delayed extraction sites, complications, preventing and solving problems, TEETH IN A DAY™ and Teeth In An Hour™ for the maxilla and mandible and the philosophy of ultimate dental/facial makeovers.

Teaching Methods: Lectures, slides, videos, hands-on surgical and prosthetic procedures. Live surgery observed.

Seminar Includes: Certificate of attendance, course materials, lunch and refreshments.

**Nobel Biocare is an ADA CERP Recognized Provider. The formal continuing education programs of this sponsor are accepted by the AGD for Fellowship/Mastership credit. Participants are eligible for 24 hours of continuing education credit. Continuing education credits issued for participation in this CE activity may not apply towards license renewal in all States.*

For more information or to register:
call 215-643-5881 or fax 215-643-1149

The Institute For Facial Esthetics Reserves the right to cancel the course at any time with no responsibility other than full refund of tuition paid. No refunds made within 48 hours of the course.

swelling. When compared to those receiving implants placed following a standard protocol, patients receiving Nobel Biocare's Teeth in an Hour™ typically exhibit very little to no pain or discomfort. This is due to the brevity of the surgical procedure and the fact that the gum tissue is subjected to minimal trauma during placement of the Brånemark implants.

Today Bill, who enjoys an active lifestyle, professes to be "awed" by the outcome of his surgeries. "I always wanted to look like Don Johnson," he confides. He smiles – the smile of a man who has achieved a dream.

Acknowledgements:

Fort Washington Dental Lab, Inc.
Bob Winkelman, CDT, MDT


Ark Developers and Technicians
Dr. Matts Andersson
Andreas Pettersson
Viktor Rennemark,
Nobel Biocare, Sweden

Montgomery Hospital Radiology Department
Dr. John Devenney, Chairman
Mrs. Cheryl Steward, Radiology Director

TIAH Coordination
Pat Martin
Christine Raines

Harvest Technology, Inc.
Bob Regan, North American Sales Manager

A Whole New World in Just One Day



TEETH IN A DAY™


Dr. Glenn Wolfinger and Dr. Thomas Balshi, Board Certified Prosthodontists present real life stories about actual patients experiencing Teeth In A Day™ Procedures step by step.

To Request a free Teeth In A Day™ Video Call Prosthodontics Intermedica at 215-646-6334 or email us at PITEAM@aol.com



Prosthodontic Insights is published by Prosthodontics Intermedica and distributed without charge to qualified individuals. Please request a subscription on your organization's letterhead.

Prosthodontics Intermedica
467 Pennsylvania Avenue, Suite 201,
Fort Washington, PA 19034 U.S.A.
Tel: 215-646-6334 Fax: 215-643-1149
Email: PITEAM@aol.com



A Patient's Guide to Dental Implants

\$14.95 plus shipping and handling

By Thomas Balshi, DDS, William Becker, DDS, Edmond Bedrossian, DDS, Peter Wohrle, DMD

Four dental implant specialists explain dental implant treatment step by step, in a first-of-its-kind book. Among the topics the authors cover: Who is a candidate for implants?, the advantages of implants, how implants are surgically placed, how to find a qualified dentist, and follow-up care. The book is loaded with before and after photos of patients.

This book can be ordered from Prosthodontics Intermedica, Fort Washington, PA.

Write Notes Here